Operative Techniques in
Sports Medicine

Medial Ankle Ligament Injuries in Athletes

Patrick Lötscher, MD, and Beat Hintermann, MD

Ankle sprains with injuries of the lateral or medial ligament complex have a high incidence in daily life and sports. Therefore, an appropriate concept for clinical examination, diagnosis, and surgical treatment is mandatory. Although clinical presentation and treatment modalities are well described for the lateral ligaments, little is known about the medial ankle and its ligament injuries. The purpose of this article is to provide an update of clinical examination, diagnosis, and treatment for these complex ligament injuries and report the primary results of our treatment concept.
Oper Tech Sports Med 22:290-295

KEYWORDS ankle, Deltoid, reconstruction, Arthroscopy

Introduction

Ankle sprains are among the most common injuries in daily life, especially in sports. Acute ligament injuries of the ankle joint account for as many as 15%-25% of the injuries treated in medical practice[1] and 10%-30% of all injuries in sports,[2-4] thus playing an important socioeconomic role. In a systematic large-scale review, Fong et al[2] showed that ankle injury and ankle sprain incidences were highest in team sports and court games, such as rugby, soccer, volleyball, handball, and basketball.

The ankle joint and the surrounding ligaments, which are involved in stabilizing the hindfoot and in guiding passive joint motion, represent a complex structure. One of these ligaments is the deltoid ligament that spreads in a fan-shaped manner over the medial part of the ankle joint and is an important structure with regard to stability against valgus and rotatory forces. It consists of 6 distinct components: 4 superficial and 2 deep ligaments. The superficial ligaments (tibiospring ligament [TSL], tibionavicular ligament [TNL], superficial posterior tibiotalar ligament [STTL], and tibiocalcaneal ligament [TCL]) cross the ankle and the subtalar joint, while the deep components (deep posterior tibiotalar ligament [PTTL] and anterior tibiotalar ligament [ATTL]) only cross the ankle joint.[5] Because of the broad insertion of the superficial deltoid ligament on the spring ligament, this complex also plays an important role in the stabilizing function of the medial ligaments. The superficial layers of the deltoid ligament particularly limit the talar abduction, while the deep layers limit the external rotation.[6] Both deep and superficial layers are equally effective in limiting pronation of the talus.

In ankle sprains, the deltoid ligament is injured more often than generally believed.[7] Deltoid ligament injuries can also occur as concomitant injuries accompanying lateral or bimalleolar fractures. They mostly occur in a pronation-eversion mechanism at the level of the ankle joint, with a higher risk in patients with a pre-existing, increased pronation deformity of the foot, such as valgus-flat foot deformities.[8] In an arthroscopic assessment of 288 acute ankle fractures, the medial ligaments were injured more frequently than clinically expected (39.6%).[9] A further mechanism of deltoid ligament injuries is the supination-external rotation injury, in which stage IV also includes the tears of the deltoid ligaments due to the excessive lateral rotation of the talus. In addition, this lateral rotation can result in tears of the tibiofibular and interosseous ligaments at the syndesmosis.

The purpose of this article is to provide an update of clinical examination, diagnosis, and treatment for these complex medial ligament injuries and report the primary results of our treatment concept.

Clinical Findings and Diagnosis

Patients with an acute injury of the medial ligaments usually give a history of an eversion-pronation trauma and pain in the anteromedial part of the ankle joint. Generally, a hematoma and tenderness along the deltoid ligament are present. Furthermore, loading of the ankle joint is critical and associated with a feeling of instability.

Department of Orthopaedic Surgery and Traumatology, Cantonal Hospital Baselland, Liestal, Switzerland.
Address reprint requests to Beat Hintermann, MD, Department of Orthopaedic Surgery and Traumatology, Cantonal Hospital Baselland, Rheinstrasse 26, Liestal 4410, Switzerland. E-mail: beat.hintermann@ksbl.ch

http://dx.doi.org/10.1053/j.otsm.2014.09.009
1060-1872/

Figure 1 Anterior drawer test. To assess the medial ankle instability, the examiner grasps the calcaneus and the hindfoot with one hand, while stabilizing the distal tibia with the other hand. In a slight plantarflexed position, the hindfoot can be translated anteriorly in the case of ligament insufficiency. (Color version of figure is available online.)

In cases where medial ankle instability has become a chronic problem, making an accurate diagnosis may be more demanding. Again, paying attention to a patient's history and the physical examination of the affected foot are the most important steps. These patients usually report a medial or anteromedial "giving way", especially while walking down a hill or stairs. A hallmark in getting the diagnosis is the palpation pain at the medial gutter of the ankle joint.[7] Not only do the injured ligaments themselves, but the synovitis of the medial part of the ankle joint are also responsible for this anteromedial pain. The laxity of the medial ankle can be detected manually by the examiner performing a varus-valgus stress test and the anterior drawer test (Fig. 1). While standing on both feet, the laxity of the medial ankle can be seen in a more pronounced hindfoot valgus and pronation of the affected foot when compared with the contralateral unaffected foot. This deformity typically disappears when the patient is asked to stand on tiptoe (Fig. 2).

In the case of secondary posterior tibial muscle dysfunction, tenderness along this tendon can be found. Furthermore, a loss of supination strength may be present, and thus the valgus deformity typically does not disappear when patients are asked to go on tiptoe. Other common concomitant injuries are listed in Table 1.

A further important clinical method is gait analysis, which allows detection of a pre-existing valgus-flat foot deformity in the contralateral foot. This is known to be a risk factor for pronation-eversion trauma.

Figure 2 In the upper left image, the patient shows an increased hindfoot valgus and forefoot pronation. When standing on tiptoe, these findings disappear because of the strength of the intact posterior tibial muscle. If the patient is asked to activate the left anterior tibial muscle, the valgus-pronation deformity also disappears (lower right image).

Table 1 Common Concomitant Injuries Associated With Medial Ligament Injury

Tibial tendon dysfunction
Fibular fractures (Weber-type B and C)
Syndesmotic disruption
Rotational instability with insufficiency of the lateral ligaments
Spring ligament injuries

Figure 3 Standard weight-bearing radiographs and hindfoot alignment view of a patient with medial ankle instability. The upper left image shows the anteroposterior view of the ankle joint with a gaping at the medial side of the joint space, thus insufficiency of the deltoid ligament should be suspected. In addition, abduction of the midfoot and forefoot and internal rotation of the talar head can be seen in the dorsoplantar view of the foot (lower right image). However, this is not a consistent finding, and it cannot be used to differentiate the status of posterior tibial dysfunction. (Color version of figure is available online.)

Standard radiographs are used to exclude fractures after the acute trauma and other bony pathologies. We do not recommend the use of stress radiographs anymore because of the lack of additional information and the potential to further damage the injured structures. In the chronic stage of medial ankle instability, standard weight-bearing radiographs are taken to assess segmental deformities in all 3 planes. A hindfoot alignment view may also be helpful (Fig. 3). A magnetic resonance imaging may help to see a weakening or avulsion from medial malleolus, but in general, it is not beneficial to make the diagnosis.

Conservative Treatment

Conservative treatment may include physical therapy such as muscular strengthening, proprioception training, and coordination training. It may also be supplemented by orthotics with a medial support, bracing, or taping. If conservative treatment has failed, surgical treatment is necessary.

Operative Techniques

Arthroscopy

Ankle arthroscopy allows assessing the degree and pattern of ankle instability of both the medial and the lateral sides. Generally, injuries to the deltoid ligament occur at the proximal insertion site, and its insertion zone at the medial malleolus shows a naked area of periosteum where the ligament is detached (Fig. 4).[7] Furthermore, associated lesions such as cartilage lesions can be identified. An arthroscopic classification of the medial ankle instability is shown in Table 2.

The following maneuvers allow the assessment of the instability:

- "axial traction" to quantify the opening of the tibiotalar space and test the possibility of inserting a 5-mm arthroscope into the tibiotalar joint space

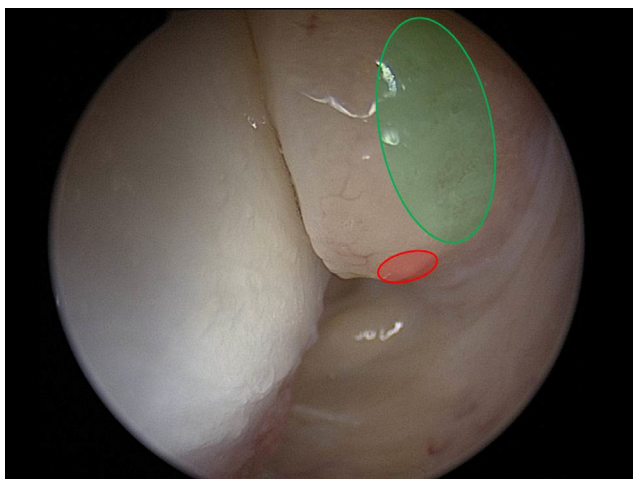

Figure 4 Arthroscopical view of the talus (left) and the medial malleolus (right). The deltoid ligament is detached from the medial malleolus and the insertion zone at the anterior border of the medial malleolus is exposed (green shaded area: insertion of the tibionavicular and tibiospring ligament; red shaded area: insertion of the tibiocalcaneal ligament). (Color version of figure is available online.)

Table 2 Arthroscopic Classification of Medial Ankle Instability and Associated Findings According to Valderrabano et al[10]

	Superficial or Anterior Deltoid Ligament	Deep or Posterior Deltoid Ligament	Periosteal Scarring on the Medial Malleolus	Medial Osteophytes	Tibiotalar Space (mm)	Additional Lateral Ankle Instability
Stage I	Elongated or partially torn or avulsion	Normal	+	+	2-5	No
Stage II	Torn	Elongated or partially torn	++	++	2-5	No
Stage III	Torn	Elongated or partially torn	+++	+++	>5	Yes
Stage IV	Torn	Torn	++++	++++	>5	Yes

- "talar anterior draw" to asses the medial and anteromedial instability
- "valgus stress" to detect laxity or instability of the medial ligaments
- "varus stress" to detect laxity or instability of the lateral ligaments

Ankle arthroscopy may also allow treating of associated lesions such as removal of floating cartilage, debridement, or microfracturing.

Surgical Procedures

A slightly curved incision, 4-8 cm in length, is made, starting 1-2 cm proximal to the medial malleolar tip and going down toward the medial aspect of the navicular bone. After the dissection of the fascia, the deltoid ligament and the posterior tibial tendon are exposed. All superficial layers of the deltoid ligament (eg, tibiocalcaneal, tibiospring, and tibionavicular) and the spring ligament are carefully assessed (Fig. 5). The extent and location of ligament injuries are determined as following: injuries at the proximal part of the deltoid (type-I lesions), injuries at the intermediate part of the deltoid (type-II lesions), and injuries at the distal part of the deltoid and spring ligaments (type-III lesions).[8]

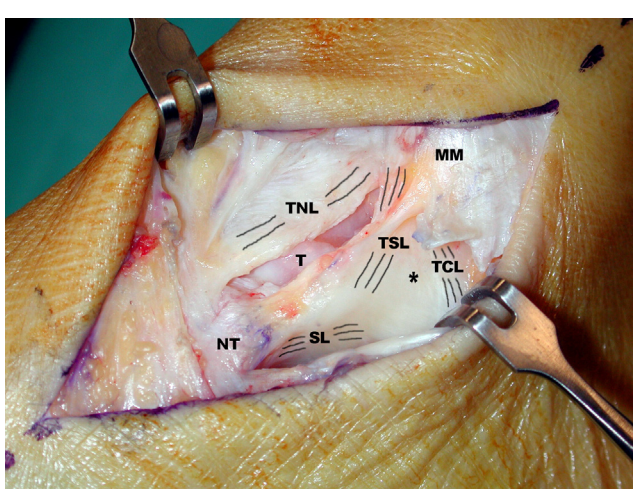

Figure 5 Surgical exposure to the medial ligaments in a type-II lesion. The posterior tibial tendon is seen under the lower retractor. MM, medial malleolus; NT, navicular tuberosity; *, fibrous septum interval; SL, spring ligament; T, talus; TCL, tibiocalcaneal ligament; TNL: tibionavicular ligament; TSL: tibiospring ligament. (Color version of figure is available online.)

In *type-I lesions*, the insertion area at the anterior aspect of the medial malleolus is exposed. These lesions typically originate in the interval area, the small fibrous septum between the tibiocalcaneal and tibiospring ligaments. The insertion area at the anterior border of the medial malleolus is roughened and an anchor is placed 4-6 mm above the tip (eg, anterior colliculus) of the medial malleolus. The detached ligament is taken by the suture and the open interval is firmly closed.

In *type-II lesions*, the incompetent and typically hypertrophic ligament is divided into 2 flaps. The deep part, which has its origin at the navicular tuberosity, is fixed to the medial malleolus using a bony anchor, as it is done when treating a proximal lesion (Fig. 6). The superficial part, which has its origin at the medial malleolus, is fixed distally to the superior edge of the navicular tuberosity using another bony anchor.

In *type-III lesions*, a bony anchor is used to fix the detached deltoid and spring ligaments to the navicular tuberosity. If the remaining tissue of the spring ligament is of bad quality, the distal part of the posterior tibial tendon is used to augment the ligament reconstruction.

In patients where the ankle instability persists and ligament quality is insufficient (less than 5%), direct reconstruction with anchors may not be possible. In these cases, autologous reconstruction using a free tendon graft (eg, plantaris tendon graft) should be considered (Fig. 7). The graft is passed through 2 drill holes of 3.2 mm at 2-8 mm above the medial malleolar tip and through another dorsoplantar drill hole in the navicular bone. Holding the foot in a neutral position, the graft is fixed with resorbable sutures under a slight tension. Attention has to be paid to reconstruct the tendon in a strict anatomical position and to not overtighten the ligament construct.

Incompetence of deep deltoid ligament subsequently to an injury typically results in a valgus instability of talus, which is seen by a tilt into valgus within the mortise while the foot is loaded. This condition is, in most cases, associated with a valgus misalignment of the hindfoot. The treatment strategy for this most disabling condition is still a question to debate, as most proposals (from in vitro studies) failed to be successful in the clinical application.

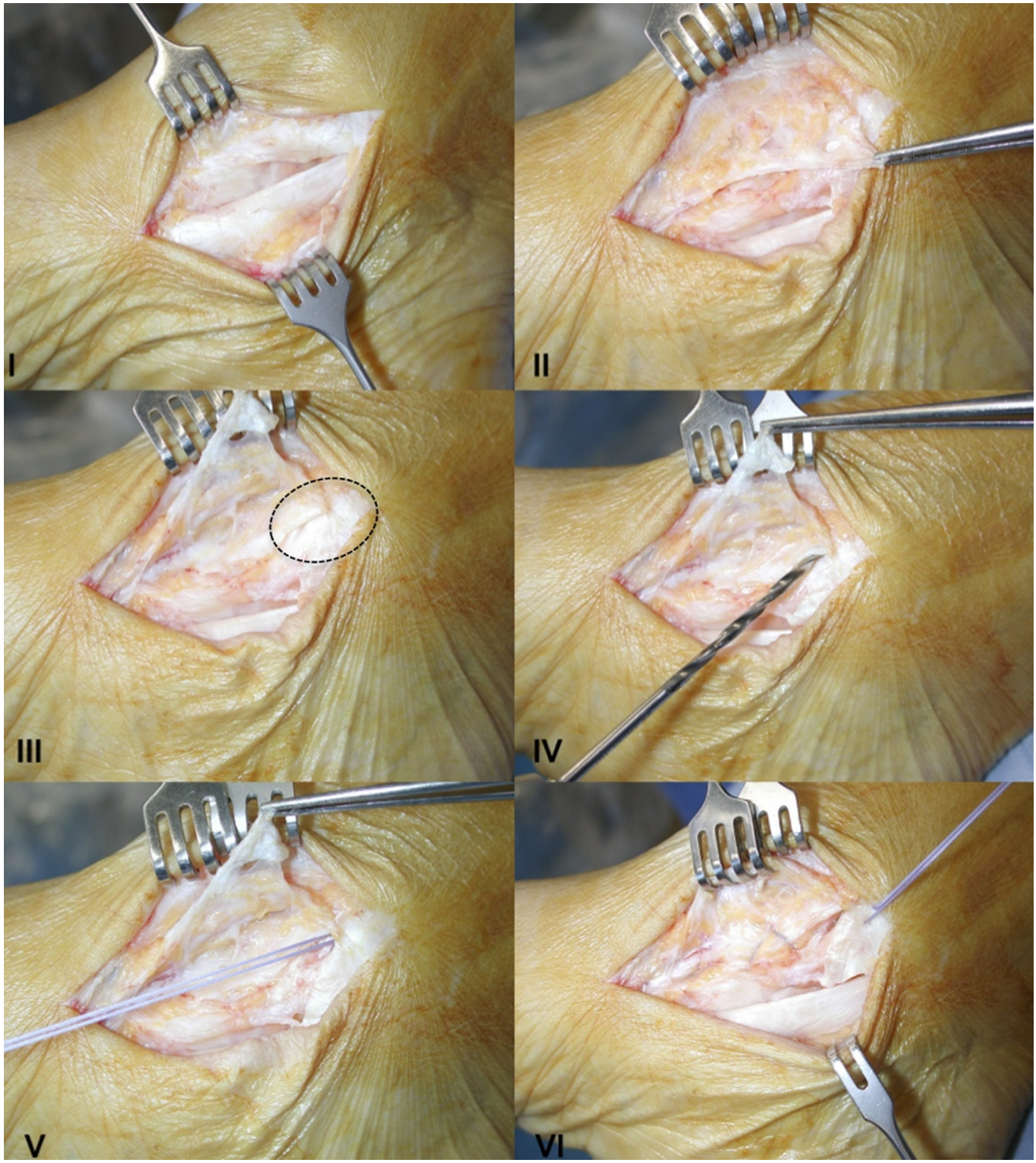

Figure 6 Operative technique for type-II lesions. A short incision is made 1-2 cm proximal to the medial malleolus going down toward the medial aspect of the navicular bone. The fascia is dissected and the posterior tibial tendon is exposed by opening its tendon sheath (I and II). Then the ligament injury is detected and a bony anchor is placed (III, IV, and V) above the tip of the medial malleolus (III, center of dotted line). The ligament tear in the superficial part is closed by the suture of the bony anchor (VI). (Color version of figure is available online.)

Additional Surgical Procedures

Calcaneal lengthening osteotomy: In patients with an excessive pronation deformity and abduction of the forefoot, a lengthening of the lateral column may be considered to bring the foot into a neutral position.[11]

Talonavicular Arthrodesis: In the presence of an excessive lesion of the tibionavicular and spring ligament, a talonavicular arthrodesis may be considered. Although isolated ligament reconstruction might be preferred to stabilize the ankle joint in athletes and active patients, talonavicular arthrodesis may be a

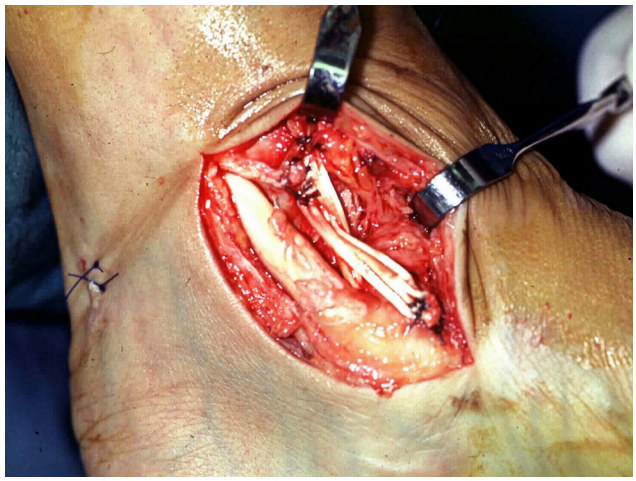

Figure 7 Reconstruction of a medial ankle instability using a plantaris tendon graft. (Color version of figure is available online.)

valuable option for obese, nonactive patients to obtain a stable foot.

Postoperative Protocol

After ligament reconstruction with or without additional bony procedures, the foot is protected in a cast for 6 weeks. After safe wound healing is obtained, the patient is allowed weight bearing as tolerated. After cast removal, the foot is further protected in a removable walker for another 4-6 weeks, and the rehabilitation program is started including active and passive mobilization, proprioceptive exercises, and muscle training. After this period of time, the walker is only used in uncontrolled or heavy activities.

Summary and Casuistic

Medial ankle ligaments are more often involved in ankle sprain injuries than generally believed and thus have often been forgotten up to date. Therefore, careful clinical investigation of the acutely injured ankle is mandatory as it is also the case for chronically unstable ankles. Standard radiographs, if possible under weight-bearing, may serve to identify associated bony injuries or deformities that may also be addressed when surgical treatment is considered.

Surgical management of acute tears of the medial ankle ligaments is recommended if there is a complete rupture and no remaining structures against valgus stress can clinically be detected. In chronic injuries of the deltoid ligament, surgical reconstruction should be considered on all involved ligaments of the medial and lateral aspect of the ankle. Although isolated medial ankle instability can occur, the lateral ankle ligaments are more often involved as expected. In as many as 77% of patients with a medial ligament instability, a ligamentous avulsion of the lateral ligaments was found on arthroscopy.[7] In these cases of "combined rotational ankle instabilities," it remains uncertain if primarily the medial ankle injury caused a lateral avulsion due to an overuse and attenuation because of the repetitive rotatory shift of the talus within the ankle joint or if the lateral instability caused the chronic overload of the medial ligaments.

In a series of 52 patients with a superficial deltoid ligament insufficiency, Hintermann et al[7] found a type-I lesion of the superficial deltoid ligament in 71%, a type-II lesion in 10%, and a type-III lesion in 19% of the cases. Repair of the deltoid ligament was performed in all 52 cases as described previously; it was necessary to repair the spring ligament in 24% and the lateral ligaments in 77%. The clinical results in this series was considered as "good to excellent" in 90%, "fair" in 8%, and "poor" in 2%. This appears to show that the management of deltoid ligament injuries as described previously leads to favorable results; therefore, we will continue to use this protocol in the future.

References

1. Hintermann B, Valderrabano V: Diagnostik und Behandlung der Instabilitäten. Sportorthopädie-Sporttraumatologie 17:153-158, 2001
2. Fong DT, Hong Y, Chan LK, et al: A systematic review on ankle injury and ankle sprain in sports. Sports Med 37(1):73-94, 2007
3. Lin CF, Gross ML, Weinhold P: Ankle syndesmosis injuries: Anatomy, biomechanics, mechanism of injury, and clinical guidelines for diagnosis and intervention. J Orthop Sports Phys Ther 36(6):372-384, 2006
4. Waterman BR, Belmont PJ, Cameron KL, et al: Risk factors for syndesmotic and medial ankle sprain: Role of sex, sport, and level of competition. Am J Sports Med 39(5):992-998, 2011
5. Hintermann B: Medial ankle instability. Foot Ankle Clin 8:723-738, 2003
6. Close JR: Some applications of the functional anatomy of the ankle joint. J Bone Soint Surg Am 38 A:761-781, 1956
7. Hintermann B, Valderrabano V, Boss AP, et al: Medial ankle instability—An exploratory prospective study of 52 cases. Am J Sports Med 32:183-190, 2004
8. Hintermann B, Knupp M, Pagenstert GI: Deltoid ligament injuries: Diagnosis and management. Foot Ankle Clin 11:625-637, 2006
9. Hintermann B, Regazzoni P, Lampert C, et al: Arthroscopic findings in acute fractures of the ankle. J Bone Joint Surg Br 82:345-351, 2000
10. Valderrabano V, Hintermann B: Diagnostik und Therapie der medialen Sprunggelenksinstabilität. Arthroskopie 18:112-118, 2005
11. Hintermann B, Valderrabano V, Kundert HP: Lengthening of the lateral column and reconstruction of the medial soft tissue for treatment of acquired flatfoot deformity associated with insufficiency of the posterior tibial tendon. Foot Ankle Int 20(10):622-629, 1999