

Endoscopic fasciotomy in chronic exertional compartment syndrome of the forearm caused by heavy manual work – case report

Endoskopische Faszienpaltung beim chronischen belastungsinduzierten Kompartmentsyndrom des Unterarms durch schwere manuelle Arbeit – ein Fallbericht

Abstract

Chronic exertional compartment syndrome (CECS) of the forearm is a rare condition causing pain, tenderness, swelling, paraesthesia and muscle weakness. It is caused by a critical augmentation of the extracellular pressure of the forearm compartments induced by intensive sport or heavy manual work.

This case report describes a 33-year-old demolition worker who presented with chronic exertional compartment syndrome of both forearms induced by severe physical work. The exclusion diagnosis was made based on clinical and electro-physiological examinations. The patient was treated using a minimal-invasive one portal endoscopic fasciotomy. He resumed to full work duties with no recurrence of symptoms during strain caused by heavy lifting and carrying.

In conclusion, endoscopic forearm fascial release is a safe, efficient and minimally invasive technique that avoids the disadvantages associated with open decompression in cases of CECS and facilitates an early resumption of work.

Keywords: chronic exertional compartment syndrome, endoscopic, fasciotomy, forearm, minimally invasive technique

Zusammenfassung

Das chronische belastungsinduzierte Kompartmentsyndrom des Unterarms ist ein seltenes Krankheitsbild, das zu Schmerzen, Druckempfindlichkeit, Schwellungen, Parästhesien und Muskelschwäche führt. Ursache ist eine kritische Erhöhung des extrazellulären Drucks innerhalb der Unterarm-Faszienlogen infolge von intensiver sportlicher Aktivität oder schwerer manueller Arbeit.

Dieser Fallbericht beschreibt einen 33-jährigen Abbrucharbeiter, der sich mit einem Kompartmentsyndrom beider Unterarme vorstellte. Die Diagnose wurde als Ausschlussdiagnose basierend auf klinischen und elektro-physiologischen Untersuchungen gestellt. Die Behandlung des Patienten erfolgte mittels minimal-invasiver endoskopischer Fasziotomie durch ein einziges Portal. Er konnte wieder seine volle Arbeitstätigkeit aufnehmen, ohne Wiederauftreten der Symptome bei Belastung durch schweres Heben und Tragen.

Zusammenfassend ist die endoskopische Faszienpaltung eine sichere, effiziente und minimal-invasive Therapie bei belastungsinduziertem Kompartmentsyndrom, verbunden mit der Möglichkeit einer frühzeitigen Wiederaufnahme der Arbeitstätigkeit auch in manuell belastenden Berufen.

Schlüsselwörter: exertionelles Kompartmentsyndrom, endoskopisch, Fasziotomie, Unterarm, minimal-invasive Technik

Beate Wilmink¹
Ingo Eisenbarth²
Renato Fricker³

1 Klinik für Handchirurgie,
Campus Bad Neustadt, Bad
Neustadt/Saale, Germany

2 Praxis Orthopädie am Rhy,
Basel, Switzerland

3 Praxis Leonardo, Hirslanden
Klinik, Münchenstein,
Switzerland

Introduction

Chronic exertional compartment syndrome (CECS) is characterized by pain, paraesthesia and functional impairment induced by intensive sport or heavy work [1], [2]. The underlying pathomechanism is an increased intramuscular pressure, which decreases muscle perfusion and causes muscle exhaustion and ischemic pain [3]. Symptoms decrease when the trigger is stopped. It has been treated traditionally by open fasciotomy, which required a lengthy operation and a long rehabilitation period before regular activity could be resumed. Therefore, various less invasive techniques have been developed to reduce incision size, morbidity and recovery time.

The purpose of this study was to present a new technique for endoscopic-assisted fasciotomy of the forearm using a single mini-incision to provide full endoscopic visualization unlike “mini-open” techniques and employing only standard equipment used in endoscopic cubital tunnel surgery.

Case report

A 33-year-old right hand-dominant demolition worker presented with symptoms of trigger finger in thumb and little finger of the right hand, bilateral carpal tunnel syndrome and labour-induced tenderness and pain in both forearms, recurrent finger swelling and loss of grip strength. His medical history was unremarkable except for a juvenile-onset insulin dependent diabetes mellitus (HbA1C 7.9%).

Forearm pain persisted despite operative release of both carpal tunnels and trigger finger surgery followed by intensive ergotherapy. The patient was unable to continue working due to the incapacitating intensity of his pain. CECS of the forearm was suspected as the origin of the symptoms after further electro-physiological and clinical examination excluded other causes, such as cervical spinal stenosis and thoracic outlet syndrome.

Endoscopic fasciotomy on both forearms was finally performed 9 months after the first consultation. Intraoperative findings demonstrated a very rigid forearm fascia, especially in the distal third of both forearms, yet no other pathologies.

Surgical technique

The endoscopic set commonly used for cubital tunnel surgery was composed of a small tissue retractor, an endoscopic device that includes optic and light source, blunt dissectors, forceps, different length scissors to cut the fascia, and a bipolar scalpel (Fa. Richard Wolf, Knittlingen, Germany).

The patient was placed supine with both arms abducted at 90° on surgical tables. The bilateral procedure was performed under general anaesthesia, using a tourniquet on both upper arms inflated to 280 mmHg pressure.

For fasciotomy, a longitudinal incision of approximately 4 cm length was made on the palmar aspect of the middle third of both forearms. After subcutaneous dissection, keeping the flexor carpi radialis muscle lateral to the surgical approach, the fascia of the superficial flexor compartment was identified. Using the blunt dissector, the subcutaneous layer was divided from the underlying fascia. The fascia was then incised with scissors parallel to the landmark lines: the flexor carpi radialis and the palmaris longus muscles were kept lateral to the deep incision while the flexor carpi ulnaris muscle was kept medial to this incision.

Using the same instruments the fascia was then opened proximally, starting from the entry portal proceeding toward the medial epicondyle.

The procedure was performed under visual control by the camera at all times. Bulging of muscular fibers could be observed once the fascial tension was lost and muscular fibers appeared once it was completely dissected (Figure 1). Endoscopic control of any bleeding site was performed and the skin incision was closed by subcuticular continuous suture without drains. A sterile dressing was then placed around each forearm to finish the procedure.

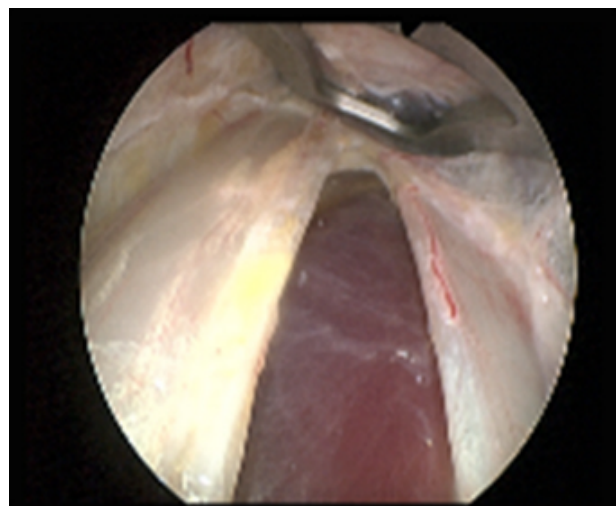


Figure 1: Endoscopic view on divided fascia with blunt dissector (above) and bare muscle fibers (bottom)

Results

The postoperative course was uneventful, no wound-related complications or clinical signs of injury of either the lateral or medial antebrachial cutaneous nerves were noted (Figure 2). The patient resumed full work duties 4 weeks postoperatively. One year after surgery, he reported complete resolution of forearm pain and paraesthesia and no limitations or pain in his daily routine or during work.

He was very satisfied with his painfree performance and therefore refused a neuro-physiological follow-up examination.

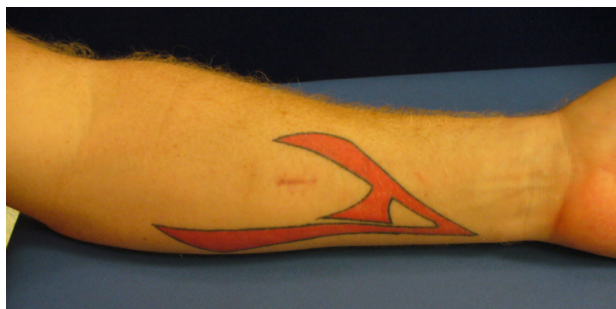

Figure 2: Left forearm with unobtrusive scar 6 weeks after surgery

Discussion

CECS of the forearm is a rare clinical condition mostly found among people performing specific sports with high exertion of forearm muscles, e.g. motocross-racing, climbing, rowing, field hockey or as in our case, heavy manual labour – usually, both forearms are affected, except for violinists [1], [2], [4]. Several etiologies have been proposed, yet muscular hypertrophy and fascia inflexibility are regarded as the two major factors. Furthermore, chronic myofibril damage due to strenuous physical activity releases protein-bound ions and leads to increased osmotic pressure, consequently decreasing blood flow within the compartment [2], [5].

The superficial flexor compartment containing the pronator teres, palmaris longus, flexor digitorum superficialis, flexor carpi radialis, and flexor carpi ulnaris muscles, is most frequently affected because of the high exertion on these muscles during prolonged sporting and working activity.

Considering this, we only performed a superficial palmar fasciectomy as in the forearm – unlike in the leg – the palmar and dorsal compartment and mobile wad compartment (brachioradialis and radial wrist extensors) are interconnected [6]. Although the most affected muscles are probably the flexor digitorum profundus and flexor pollicis longus (in the deep palmar compartment), our results are in accordance with other studies which confirmed that superficial fasciectomy is adequate to release the entire forearm [7], [8]. Fontes et al. (2003) published a series of endoscopic release of the superficial compartment with good outcome and even measured a lowered intramuscular pressure on the extensor side while only having performed palmar fasciectomy [9].

Even though there are a number of cases described, and an estimated number of unreported cases can be supposed [5], current literature provides no reliable information about incidence, distribution between the genders or predisposing factors [5], [10]. An acknowledged diagnostic algorithm does not exist.

Currently, handgrip stress tests may provide the best clinical information on chronic exertional compartment syndrome. Intracompartmental pressure testing has been considered the gold standard to diagnose CECS in the lower leg, yet no consensus exists on the value of these

measurements in the forearm [11]. Notably, Schoeffl et al. (2004) reported much lower pressure rates in the deep forearm flexor compartment in rock climbers compared to the known absolute pressure maxima, as well as the muscle relaxation pressures in the tibialis anterior compartment [2]. Jans et al. (2015) concluded from their experience with forearm compartmental pressure measurements in 154 motocross racers mainly one constant: a very painful experience for the patient [11]. Interestingly, Gielen et al. (2009) recommended MRI as a non-invasive and user-friendly alternative for both patient and practitioner to verify the clinical diagnosis of CECS [4].

The only conservative treatment to resolve this condition is to stop the trigger activity. However, this may not be a satisfying option for professional athletes or in heavy manual workers. Therefore, the only therapy in these selected cases is fasciotomy. To reduce the morbidity associated with long skin incisions, mini-open and endoscopic procedure have recently been given preference over a traditional open surgery [5], [9], [10], [12]. In our case, fasciotomy was performed endoscopically, using instruments originally designed for ulnar nerve release. This approach is minimal-invasive, but technically easy and provides full visual control with improved safety compared to open techniques. As reported in the literature, the postoperative results are excellent with a very low complication rate [9], [10], [13].

Conclusion

CECS of the forearm is rare and usually a diagnosis of exclusion, due to missing diagnostic criteria. Treatment of choice is fasciotomy. Endoscopically assisted fascial decompression is a reasonable alternative to open fasciectomy, as it reduces incision size, morbidity and recovery time and provides great safety due to direct visual control employing only surgical standard equipment.

Notes

Competing interests

The authors declare that they have no competing interests.

References

1. Detmer DE, Sharpe K, Sufit RL, Girdley FM. Chronic compartment syndrome: diagnosis, management, and outcomes. *Am J Sports Med.* 1985 May-Jun;13(3):162-70. DOI: 10.1177/036354658501300304
2. Schoeffl V, Klee S, Strecker W. Evaluation of physiological standard pressures of the forearm flexor muscles during sport specific ergometry in sport climbers. *Br J Sports Med.* 2004 Aug;38(4):422-5. DOI: 10.1136/bjism.2002.003996
3. Ardolino A, Zeineh N, O'Connor D. Experimental study of forearm compartmental pressures. *J Hand Surg Am.* 2010 Oct;35(10):1620-5. DOI: 10.1016/j.jhssa.2010.06.017

4. Gielen JL, Peersman B, Peersman G, Roelant E, Van Dyck P, Vanhoenacker F, Roeykens J. Chronic exertional compartment syndrome of the forearm in motocross racers: findings on MRI. *Skeletal Radiol.* 2009 Dec;38(12):1153-61. DOI: 10.1007/s00256-009-0746-2
5. Brown JS, Wheeler PC, Boyd KT, Barnes MR, Allen MJ. Chronic exertional compartment syndrome of the forearm: a case series of 12 patients treated with fasciotomy. *J Hand Surg Eur Vol.* 2011 Jun;36(5):413-9. DOI: 10.1177/1753193410397900
6. Chan PS, Steinberg DR, Pepe MD, Beredjikian PK. The significance of the three volar spaces in forearm compartment syndrome: a clinical and cadaveric correlation. *J Hand Surg Am.* 1998 Nov;23(6):1077-81. DOI: 10.1016/S0363-5023(98)80019-1
7. Kouvalchouk JF, Watin Augouard L, Dufour O, Coudert X, Paszkowski A. Le syndrome d'effort chronique des loges antérieures de l'avant-bras [Chronic stress-related compartment syndrome of the forearm]. *Rev Chir Orthop Reparatrice Appar Mot.* 1993;79(5):351-6.
8. Gelberman RH, Garfin SR, Hergenroeder PT, Mubarak SJ, Menon J. Compartment syndromes of the forearm: diagnosis and treatment. *Clin Orthop Relat Res.* 1981 Nov-Dec;(161):252-61. DOI: 10.1097/00003086-198111000-00032
9. Fontes D, Clement R, Roure P. L'aponévrotomie endoscopique dans les syndromes de loges chroniques d'effort à l'avant-bras: à propos de 41 cas. [Endoscopic aponeurotomy for chronic exertional compartmental syndrome of the forearm: report of 41 cases]. *Chir Main.* 2003 Aug;22(4):186-96. DOI: 10.1016/S1297-3203(03)00060-X
10. Zandi H, Bell S. Results of compartment decompression in chronic forearm compartment syndrome: six case presentations. *Br J Sports Med.* 2005 Sep;39(9):e35. DOI: 10.1136/bjism.2004.012518
11. Jans C, Peersman G, Peersman B, Van Den Langenbergh T, Valk J, Richart T. Endoscopic decompression for chronic compartment syndrome of the forearm in motocross racers. *Knee Surg Sports Traumatol Arthrosc.* 2015 Sep;23(9):2522-7. DOI: 10.1007/s00167-014-3044-z
12. Croutzet P, Chassat R, Masméjean EH. Mini-invasive surgery for chronic exertional compartment syndrome of the forearm: a new technique. *Tech Hand Up Extrem Surg.* 2009 Sep;13(3):137-40. DOI: 10.1097/BTH.0b013e3181aa9193
13. Pozzi A, Pivato G, Kask K, Susini F, Pegoli L. Single portal endoscopic treatment for chronic exertional compartment syndrome of the forearm. *Tech Hand Up Extrem Surg.* 2014 Sep;18(3):153-6. DOI: 10.1097/BTH.0000000000000056
14. Lipschitz AH, Lifchez SD. Measurement of compartment pressures in the hand and forearm. *J Hand Surg Am.* 2010 Nov;35(11):1893-4. DOI: 10.1016/j.jhssa.2010.07.006
15. Korhonen RK, Vain A, Vanninen E, Viir R, Jurvelin JS. Can mechanical myotonometry or electromyography be used for the prediction of intramuscular pressure? *Physiol Meas.* 2005 Dec;26(6):951-63. DOI: 10.1088/0967-3334/26/6/006

Corresponding author:

Dr. med. Beate Wilmink

Klinik für Handchirurgie, Campus Bad Neustadt,
Salzburger Leite 1, 97616 Bad Neustadt/Saale, Germany
Wilmink_BT@web.de

Please cite as

Wilmink B, Eisenbarth I, Fricker R. Endoscopic fasciotomy in chronic exertional compartment syndrome of the forearm caused by heavy manual work – case report. *GMS Ger Plast Reconstr Aesthet Surg.* 2016;6:Doc04.
DOI: 10.3205/gpr000039, URN: urn:nbn:de:0183-gpr0000398

This article is freely available from

<http://www.egms.de/en/journals/gpr000039/2016-6/gpr000039.shtml>

Published: 2016-06-21

Copyright

©2016 Wilmink et al. This is an Open Access article distributed under the terms of the Creative Commons Attribution 4.0 License. See license information at <http://creativecommons.org/licenses/by/4.0/>.